

New Surgical Technique for Removal of Glandular Tissue of Gynaecomastia

AMIR ABDULKAREEM, M.D.; HAMDY BASHA, M.D.; MAMDOH SALAH, M.D. and ESMAIEL SHEHATA, M.D.

The Department of Plastic & Reconstructive Surgery, Al-Mataria Teaching Hospital, Cairo.

ABSTRACT

Gynecomastia is a benign enlargement of the male breast due to a physiological or pathological factor that interferes with balance between estrogen and androgen in the serum. In absence of any medical cause of gynecomastia the indications for the surgical treatment are founded on two main objectives: (1) the restoration of male chest shape and (2) diagnostic evaluation of suspected breast lesions. Before the advent of lipolysis, the surgical treatment of gynecomastia had several undesirable features. In cases of moderate to large breasts, the excision required sharp dissection and extensive undermining of tissue. Homeostasis was difficult to obtain. Postoperative hemorrhage, seroma, delayed wound healing, tissue necrosis, infection and wide poor scar was not uncommon.

Lipolysis used in combination with destruction of fibro glandular tissue during the procedure of liposuction offers a means to minimize or eliminate these undesirable sequelae of excision alone.

INTRODUCTION

Aim of work:

Evaluation of liposuction in treatment of glandular gynaecomastia with removal of glandular tissue through small incision used in liposuction.

MATERIAL AND METHODS

Twenty patients with true glandular gynaecomastia included in this study; mean Age between 22 yrs.; mean Weight between 67kgm.; mean height between 167cm. All patients were investigated by; complete blood picture, liver function, renal function, prothrombin time, partial prothrombin time, chest X-ray, free testosterone, FSH, some patients investigated for thyroid function, other investigated for adrenal function through Estradiol level.

Operative procedure:

Prophylactic antibiotic (Unasyn IV) was given preoperatively. Sterilization by Betadine from the

clavicle down to the umbilicus. Toweling to the whole body exposing the area of both breasts. General anesthesia is the preferred method of anesthesia with the patient supine. The breast tissue is infiltrated by haemostatic solution formed from saline-adrenaline 1; 500.000 and 50ml xylocaine 2%. Each breast is infiltrated with 500 to 1000ml. of this solution by infiltration cannula and waiting for 10 minutes before liposuction. Two small incisions 0.5 to 1cm. The first one at anterior axillary line opposite to nipple; the second one at inframammary line perpendicular to nipple. A high vacuum surgical suction machine is turned on until a minimum of 25mm of mercury, sharp cannula No. 3 and 4 are used for liposuction starting with No. 4 making multiple tunnels starting through the axillary incision, then another multiple tunnels through the iframammary incision to cross the tunnels made through the axillary incision (Fig. 1). The fat is easily removed by liposuction leaving the glandular tissues as solid mass at the central part of the breast beneath the areola.

Glandular removal is done through the axillary incision after fragmentation of the glandular mass by making multiple tunnels by sharp cannula No. 3 then introduction of artery forceps through the axillary incision to catch the gland and push it out from the breast then cut it by scissor (Fig. 2). Refinement is done by rounded cannula No. 3 and 2. Washing by irrigation the site of lipolysis by saline solution. Dressing and application of chest garment.

Postoperative care; oral antibiotic is given for 3 days. The patient is seen on the third postoperative day and seventh day then tenth day. Massage with or without ultrasound can be started from second week.

RESULTS

One patient only had low free testosterone level due to primary testicular failure with small sized testicles. One patient suffered from post operative seroma that was managed by continuous aspiration. Postoperative edema almost resolved after one month. Skin echymosis was minimal in most of the

patients and resolved completely after three weeks. Skin texture and elasticity were regained completely after three months. One patient with huge gynecomastia had skin redundancy after one year from the operation that was managed by mastopexy. Sensation was intact in all patients. Neither hematoma nor skin necrosis was recorded. No dishing deformity. All patients were satisfied by the results (Figs. 3,4).

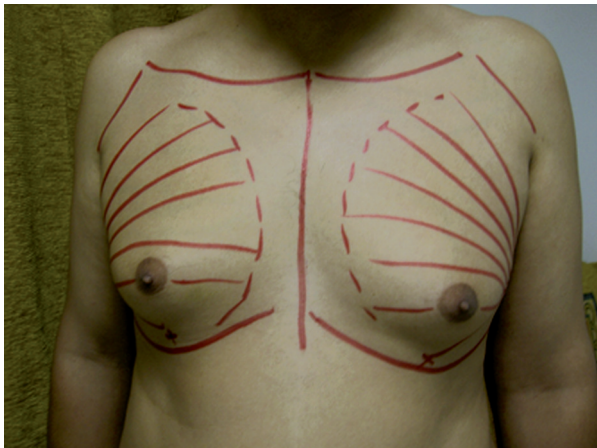


Fig. (1): Preoperative drawing showing sites of incision and tunnels of liposuction.

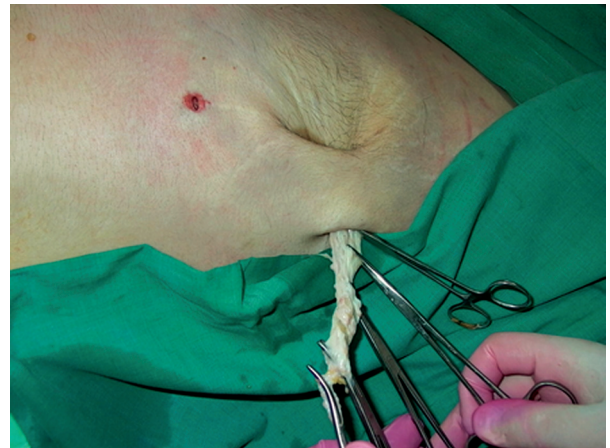

Fig. (2): Glandular removal through axillary incision of liposuction.

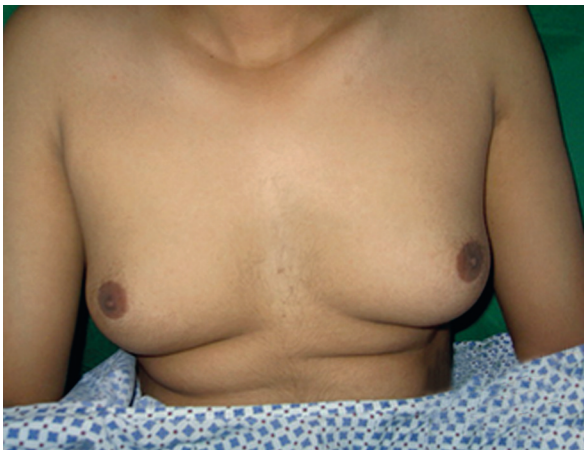

Fig. (3-A): Preoperative.

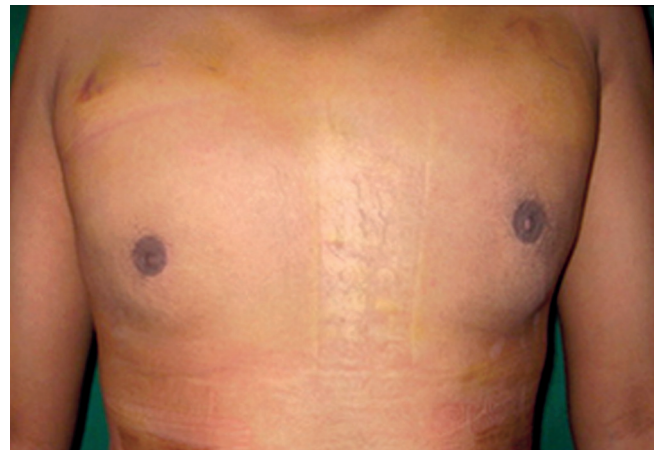


Fig. (3-B): Postoperative 2 months.

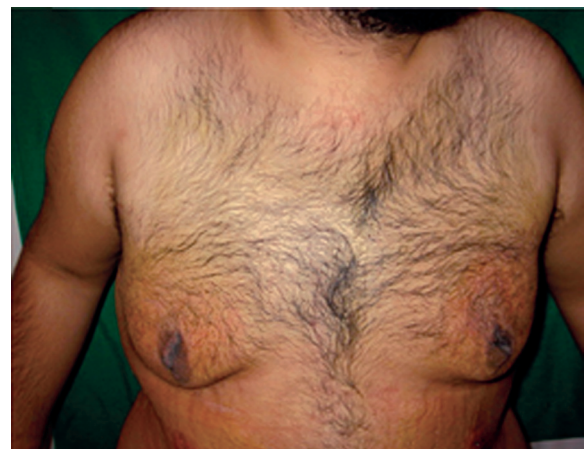
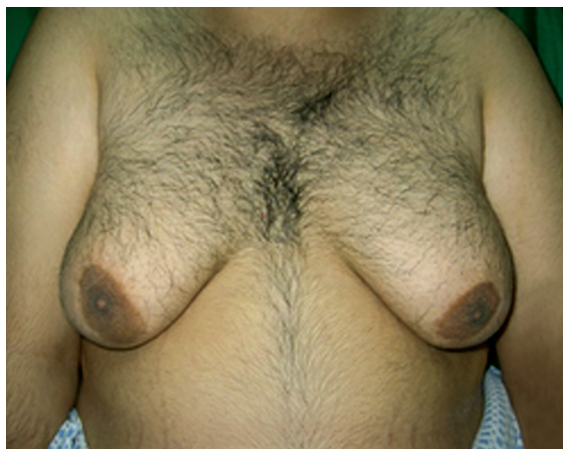
Fig. (4): Preoperative and postoperative photo of huge gynecomastia.

DISCUSSION

Historically, treatment of gynecomastia began with emphasis on removal of tissue alone [1,2]. With advances in technique, more concern was placed on the aesthetic appearance of the operative results. In 1946 Webster [3] described an intraareolar incision for gynecomastia. Subsequently, to minimize the appearance of the incision, others have masked the scar either by placing the incision transareolar [4] in the axilla [5] or by using a circumareolar incision, advancing the size of the areola and excising the surrounding tissue [6].

All of these procedures attempt to refine the appearance of incisions; however, subcutaneous undermining and excision of the tissue containing vessels and nerves is not altered and still play good role in surgery of gynecomastia. Previous reports indicate that incisions outside the nipple/areola complex [7,8], with excision of skin and adjustment of the skin envelope, leave visible scarring.

The technique of liposuction and glandular fragmentation results in very small scar and inconspicuously placed scars. Large quantities of subcutaneous tissue can be removed through a small incisions, leaving the septa connecting the skin and subcutaneous tissue, so that the tissue is pulled down as an accordion and adheres to its underlying structure. The lack of a need for skin tailoring eliminates the need for along incision and dermolipectomy.

Postoperative hemorrhage has been a relatively common complication in the treatment of moderate to large gynecomastia. Theoretically, at least, the amount of intra operative or post operative hemorrhage is less using liposuction compared with sharp dissection during subcutaneous excision of gynecomastia [10].

Most important, the iatrogenic deformities caused by extensive undermining and sharp dissection described in the literature [10] such as redundant skin, dishing deformity, depressive deformity of

the chest and nipple necrosis can be minimized or even eliminated by liposuction technique.

"An ideal method for surgical treatment of gynecomastia should be one that provides normal chest and breast contour while leaving the minimal hazardous signs of surgery". Liposuction with fragmentation of the glandular tissue and glandular extraction through small liposuction opening fulfills these criteria expressed by Huang [9].

Conclusion:

Liposuction is useful adjuvant in the treatment of gynecomastia. Destruction and fragmentation of the glandular tissue by cannula of liposuction during liposuction and extraction of this gland through liposuction incision avoid large incisions and sharp dissection to remove this gland. The advantages of this combined technique over excision alone include a more desirable contour of the chest wall and breast and lower risk of complication.

REFERENCES

- 1- Dufourmental I.L.: Incision areolaire dans la chirurgie du sein. Bull Mem. Soc. Cbir. (Paris), 20: 9, 1928.
- 2- Menville J.G.: Gynecomastia. Arch. Surg., 26: 1045, 1933.
- 3- Webster J.P.: Mastectomy for gynecomastia through a semi-circular intraareolar incision. Amer. J. Surg., 124: 567, 1946.
- 4- Pitanguy I.: Plast. Reconstr. Surg., 38 (5), 1966.
- 5- Balch C.R.: A transaxillary incision for gynecomastia. Plast. Reconstr. Surg., 61 (1), 1978.
- 6- Davidson B.A.: Concentric circle operation for massive gynecomastia to excise the redundant skin. Plast. Reconstr. Surg., 63 (3), 1979.
- 7- Letterman G. and Schurter M.: The surgical correction of gynecomastia. Amer. J. Surg., 315, 1969.
- 8- Artz J.S. and Lehman J.A., Jr.: Surgical correction of massive gynecomastia Arch. Surg., 113, 1978.
- 9- Huang T.T., Hildalgo J.E. and Lewis S.R.: A circumareolar approach in surgical management of gynecomastia. Plast. Reconstr. Surg., 69 (1), 1982.
- 10- Eade G.G.: The radial incision for gynecomastia excisions. Plast. Reconstr. Surg., 54 (4), 1974.